Pancreatic Tumor

A 75-year-old male has noted vague upper abdominal pain and backache for three weeks. This week he noted yellow skin and coke colored urine. His only prior medication is a high blood pressure pill. He drinks 2-3 alcoholic containing beverages per week. He had no apparent contact with hepatitis patients. His appetite has decreased and he lost 10 pounds. Physical exam is normal except mild upper abdominal tenderness to palpation. Blood tests revealed bilirubin 8.5 mg%, AST 120 I. U. alkaline phosphate 720 I.U. CEA is 4.5 and CA19-9 is 45 (both mildly elevated). CT scan shows enlarged head of pancreas with invasion of the portal vein **(Figure 1)**. Endoscopic ultrasound (EUS) was done next. This showed a pancreatic head tumor with portal vein invasion **(Figure 2)**. Fine needle aspirate showed adenocarcinoma (malignant cells) **(Figure 3)**. It was decided that surgical exploration and attempted removal of the tumor and portal vein was too aggressive for a patient of this age. Therefore, an ERCP was done which showed double duct sign **(Figure 4)**. Decompression (re-opening) of the obstructed bile duct was accomplished using a metal stent **(Figure 5,6)**. Jaundice resolved in the next 5-7 days. Chemotherapy with Gemcytobine was given.

Comments: Unfortunately many cases of pancreas cancer have spread too far for removal by the time detected. CT scan and EUS are the best method to stage invasion around the pancreas. An aggressive surgical approach may include reconstruction of the portal vein in selected cases. Metal stents are preferred for biliary stenting in malignancy cases as patency is twice as long as plastic.

Figure (1): CT scan shows enlarged head of pancreas with invasion of the portal vein

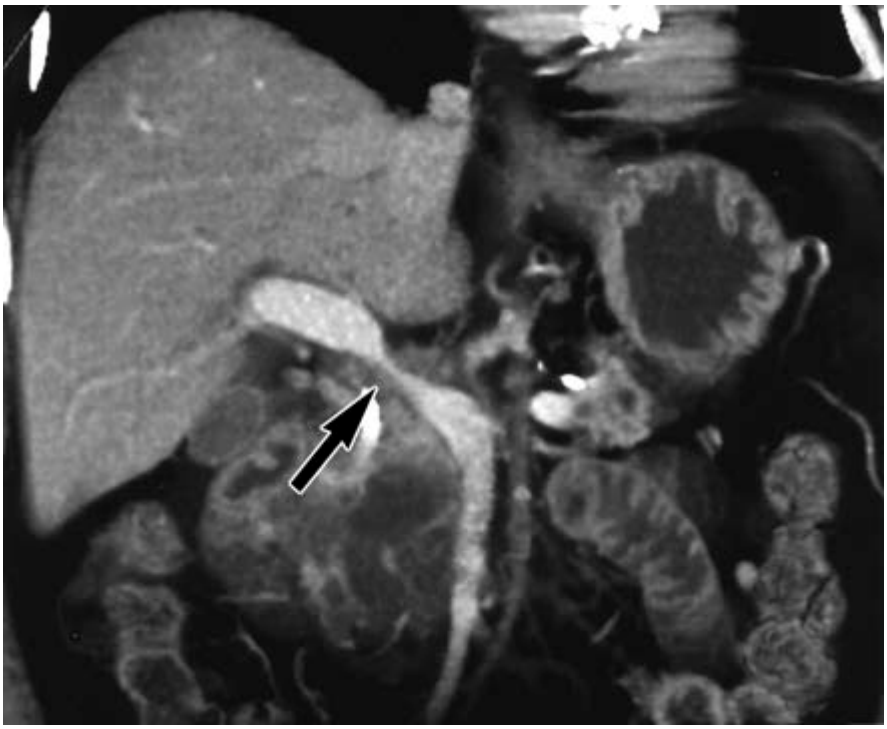

Figure (2): EUS showing a pancreatic head tumor with portal vein invasion

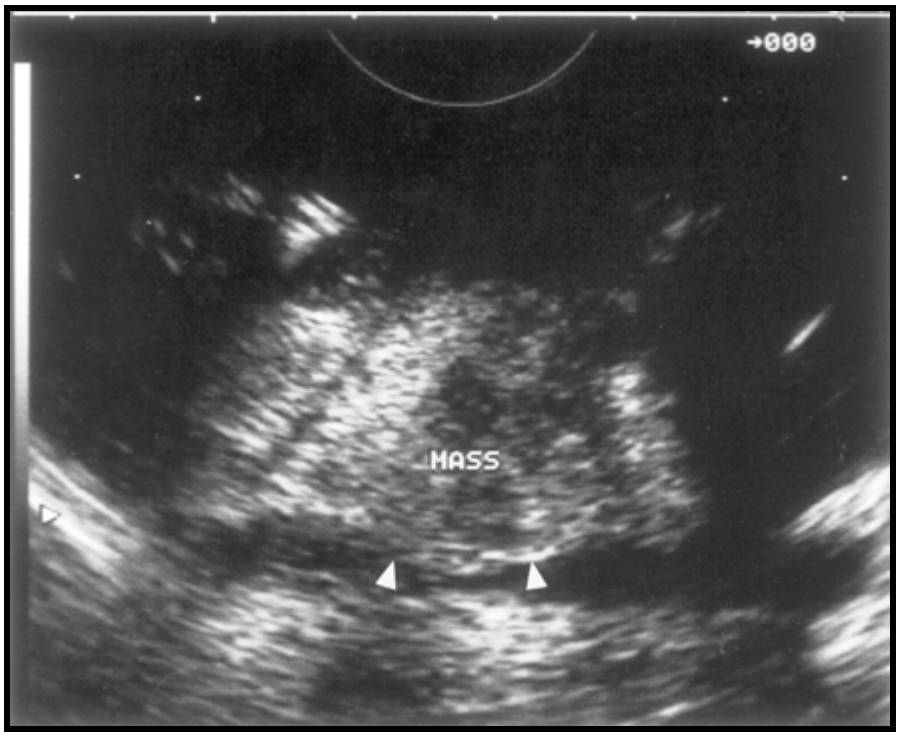
→000
MASS

Figure (3): Fine needle aspirate showed adenocarcinoma

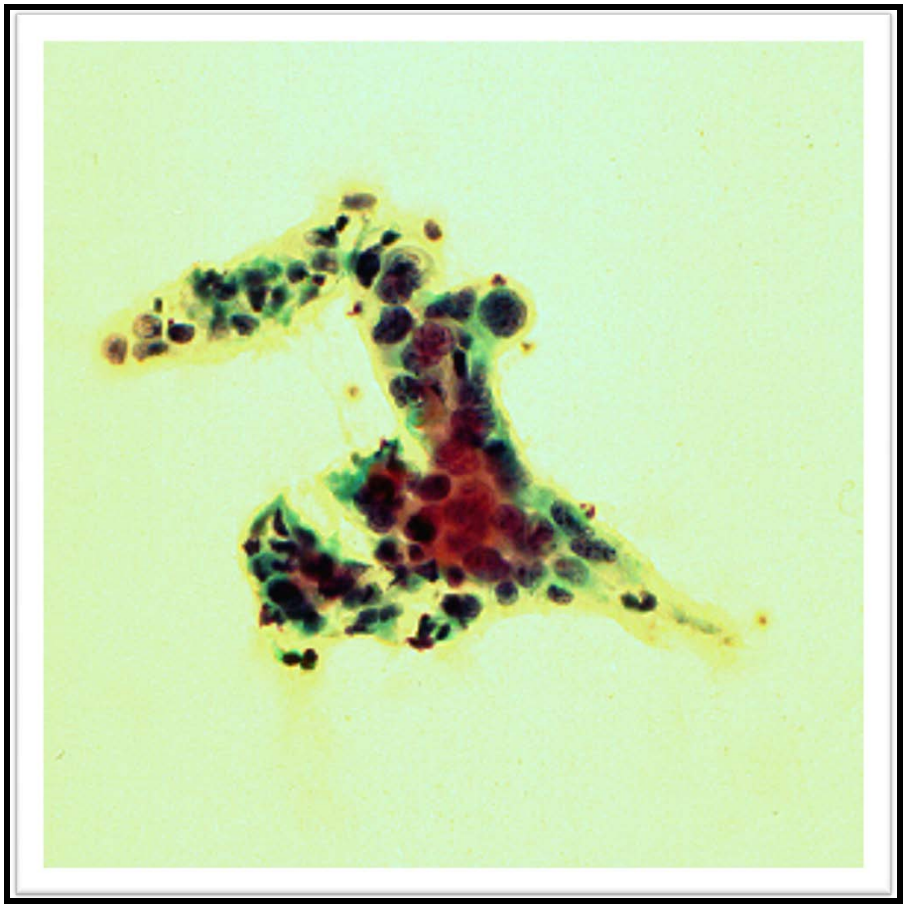

Figure (4): ERCP showing double duct sign

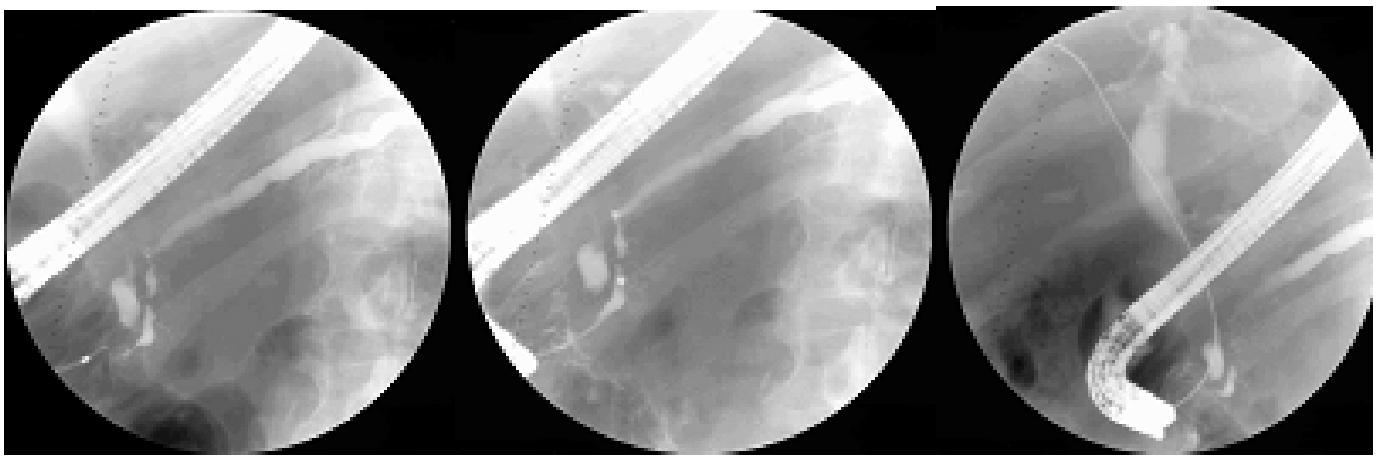

Figure (5): Decompression (re-opening) of the obstructed bile duct was accomplished using a metal stent

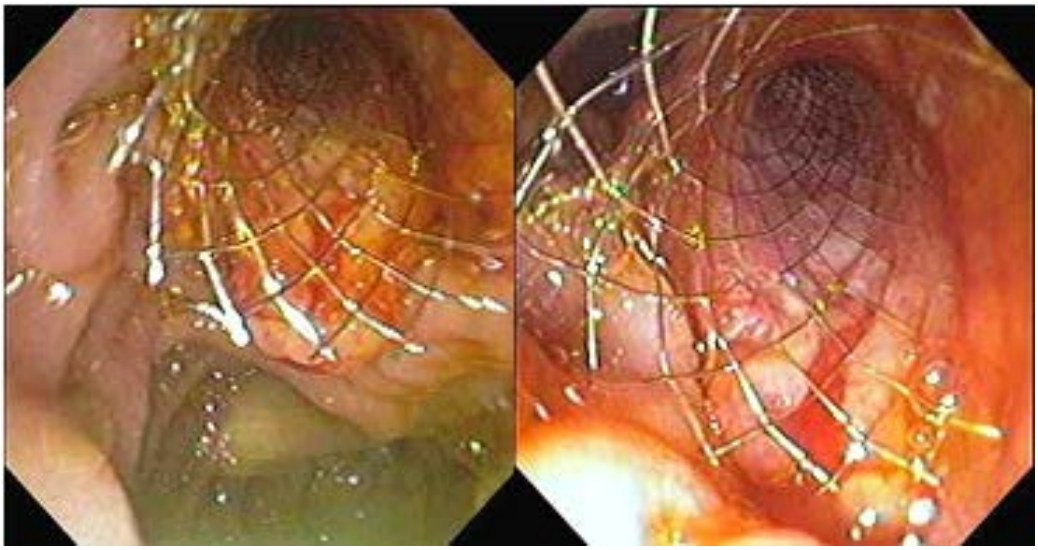

Figure (6): Fluoroscopic image of the biliary metal wall stent